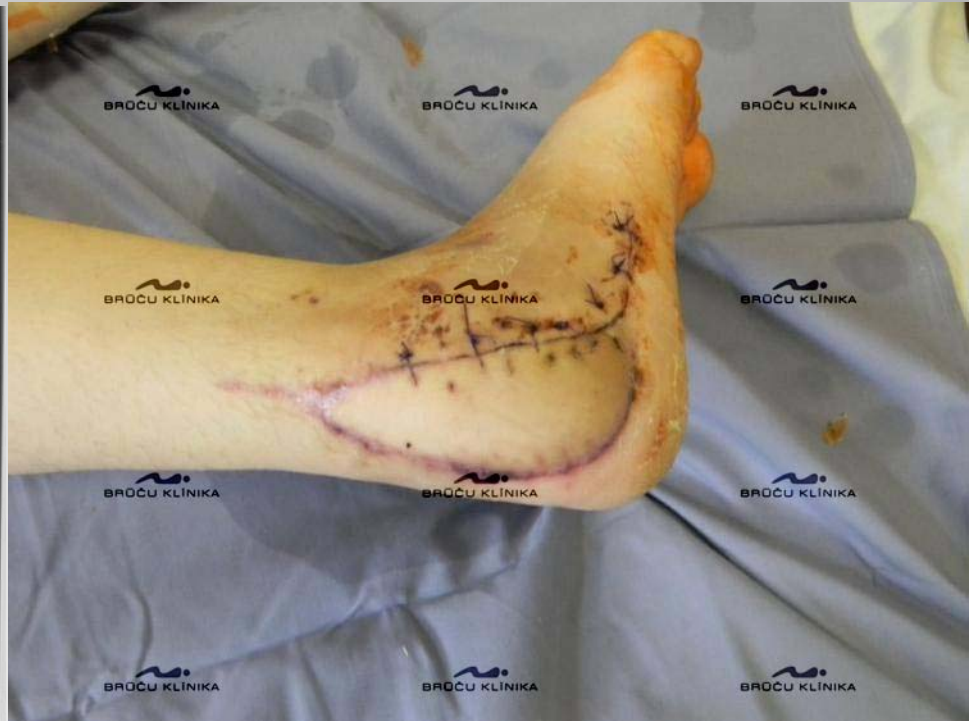
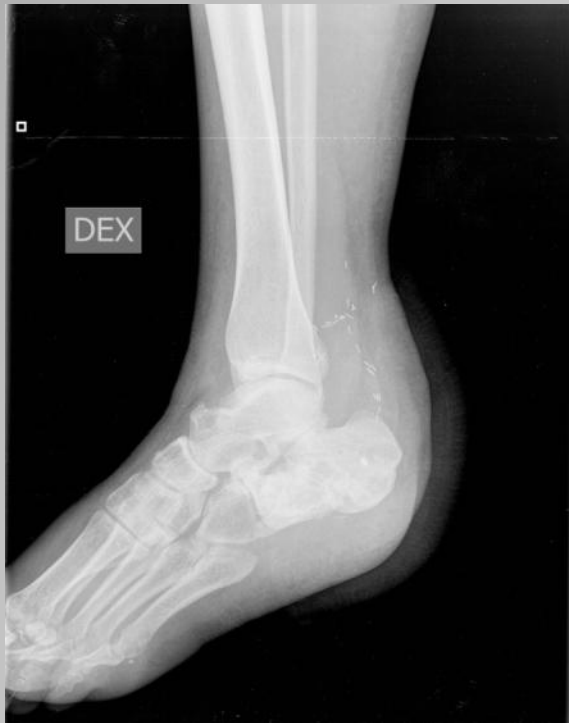
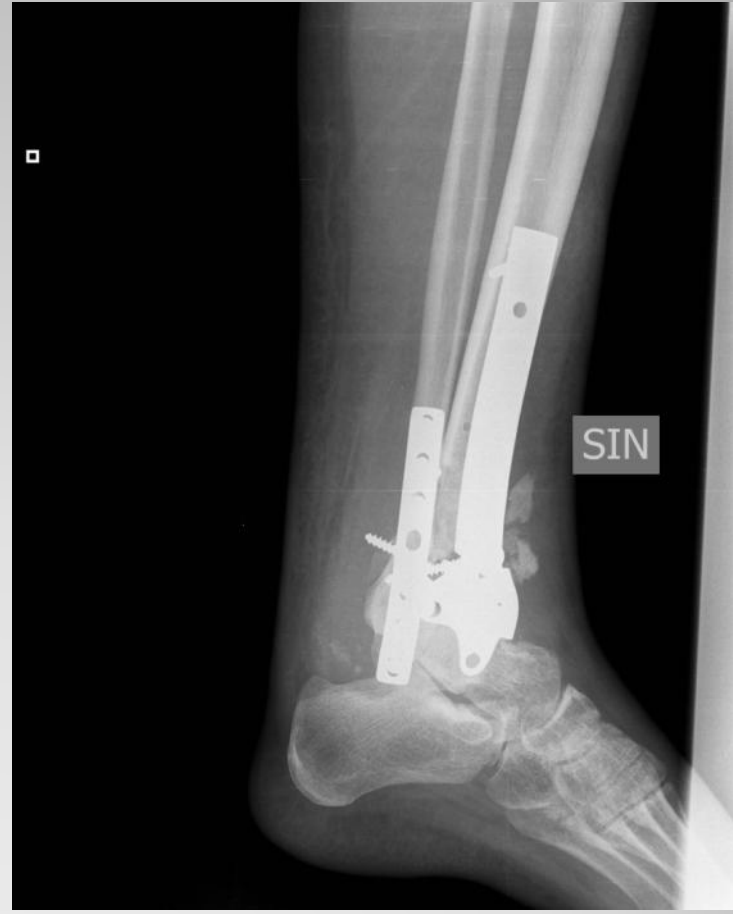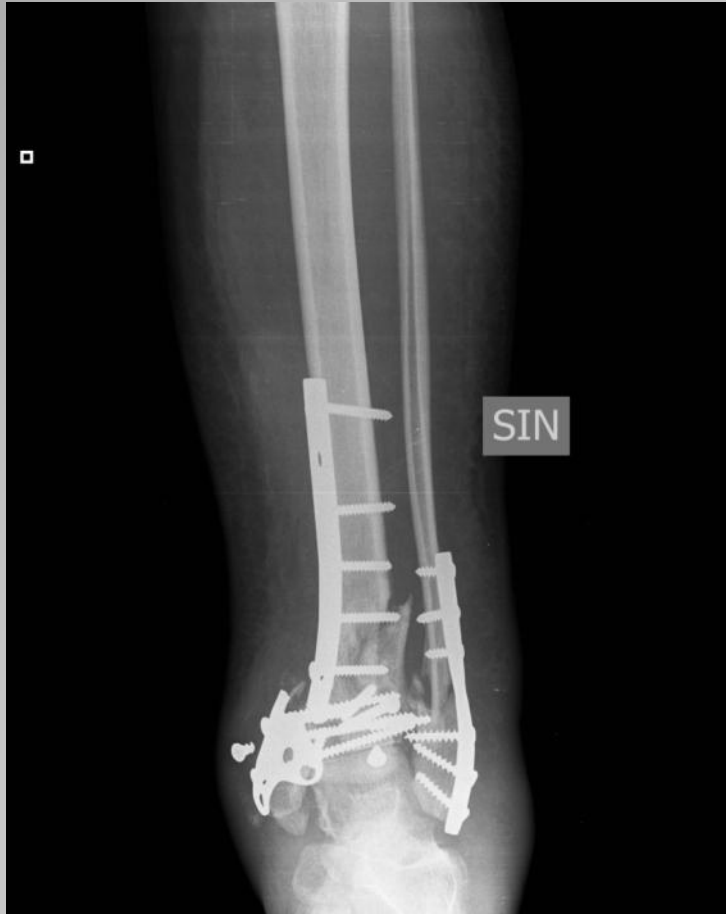# **Reconstructing lower extremity after osteomyelitis in tibia bone**

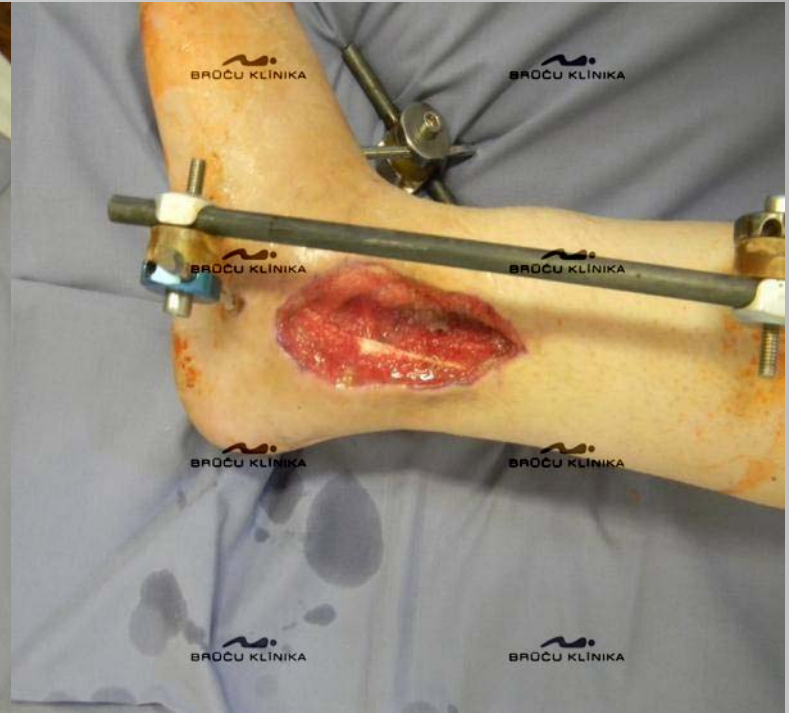
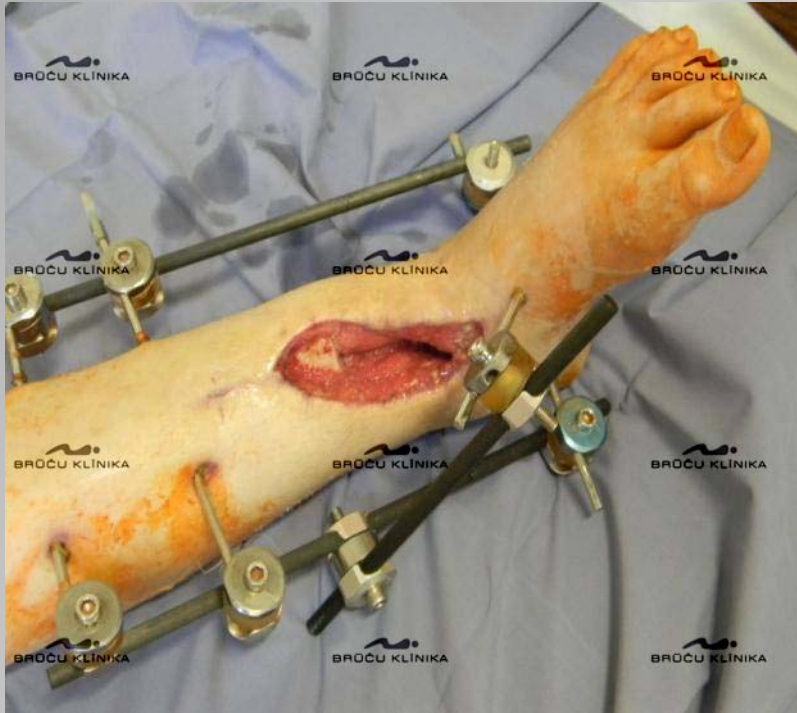Lauris Repša  
Wound clinic, Latvia

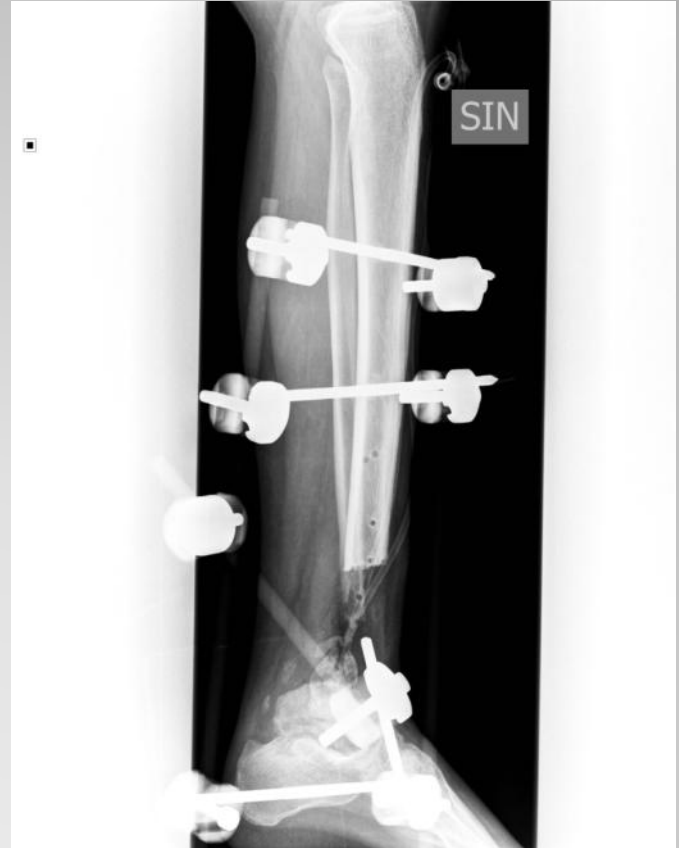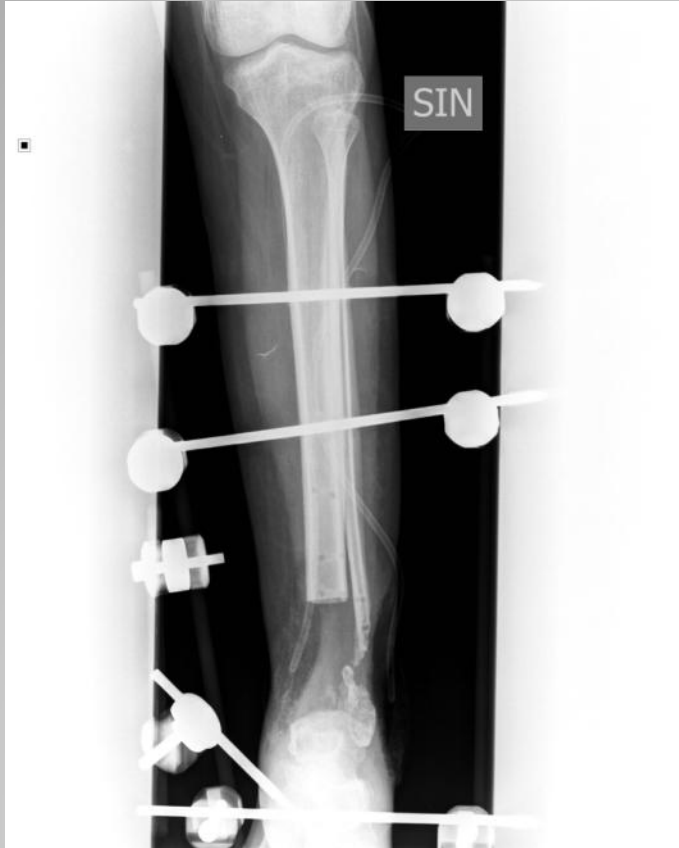## Diagnosis:

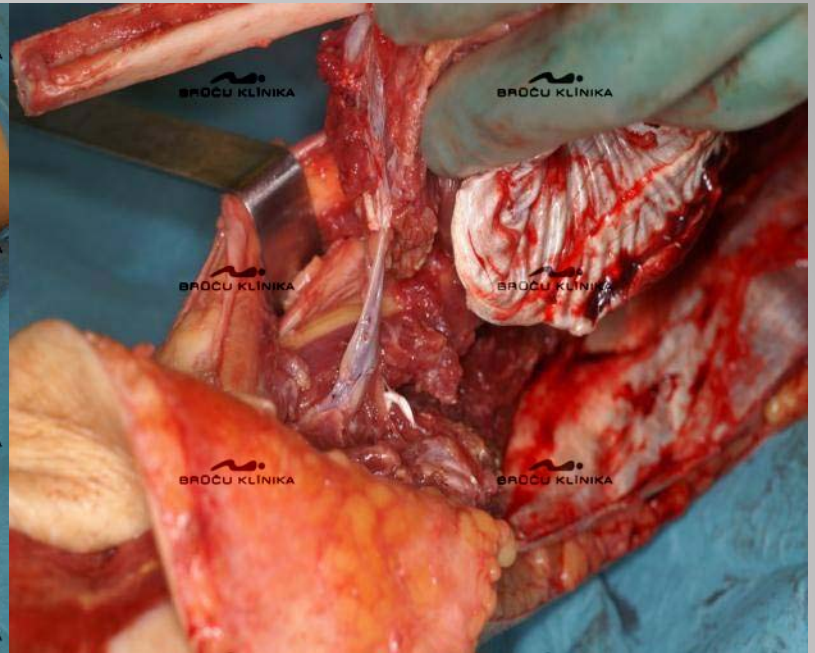
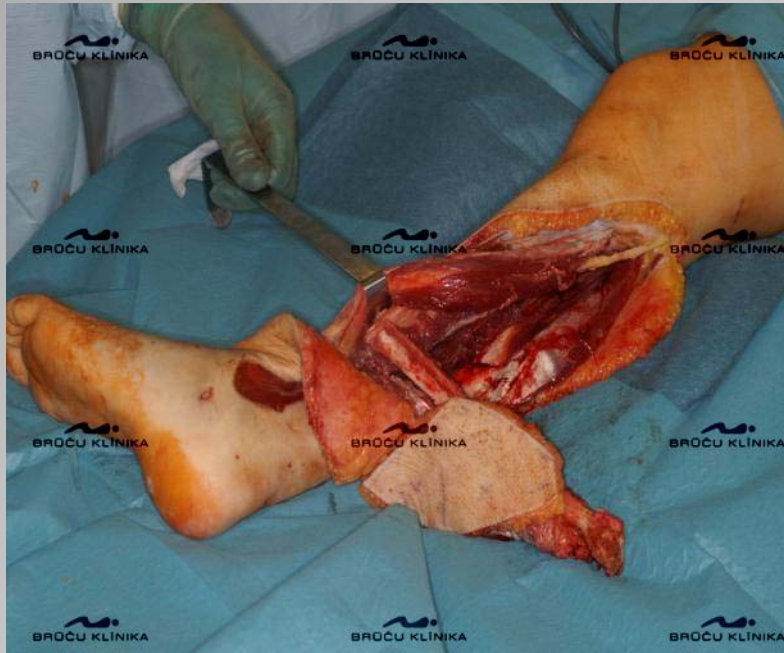
- Fracture of L2 vertebrae without spinal cord injury;
- Fracture of left tibia pilon and distal fibula;
- Fracture of right calcaneus;
- Fracture of os sacrum without dislocation.

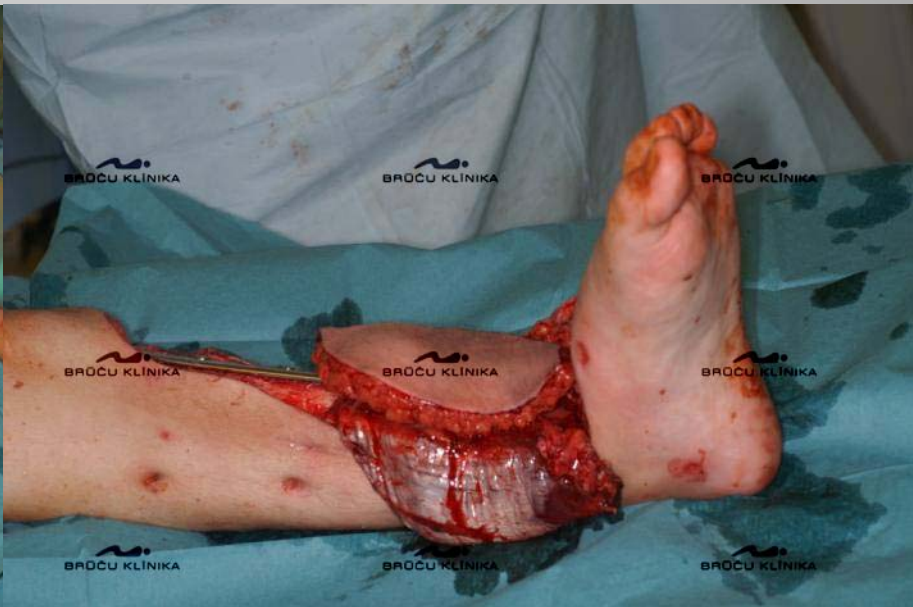
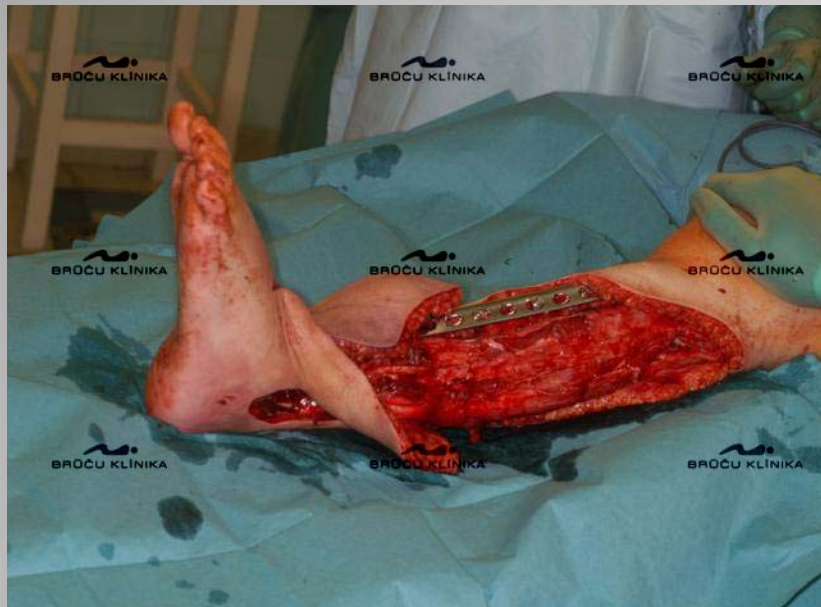




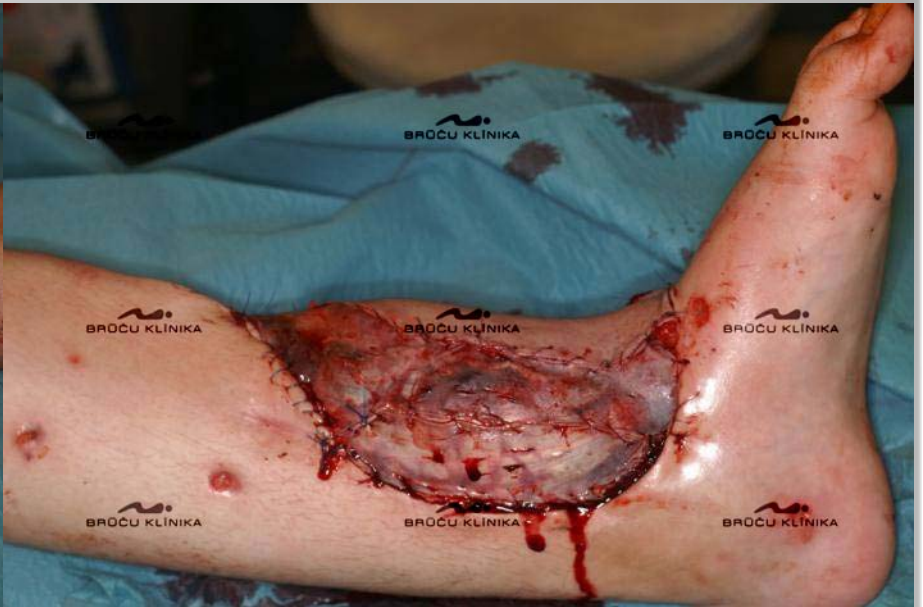
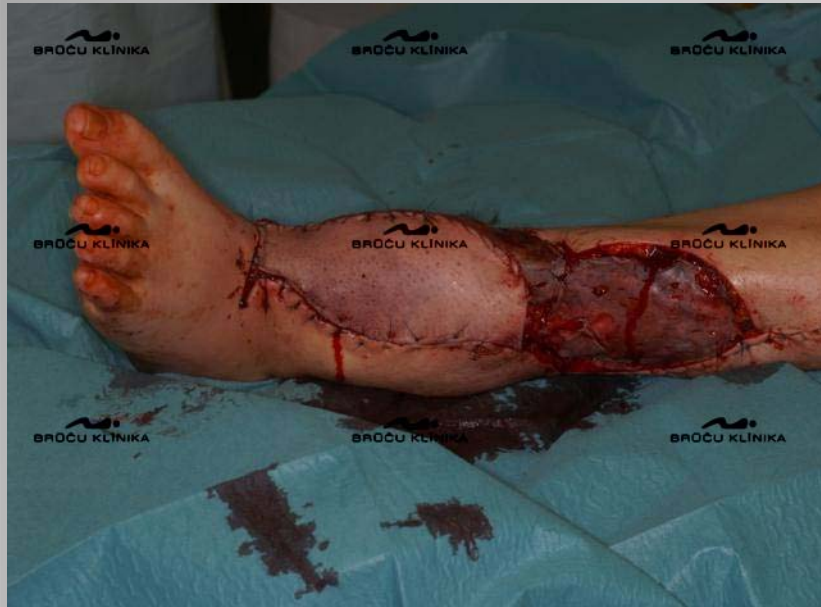


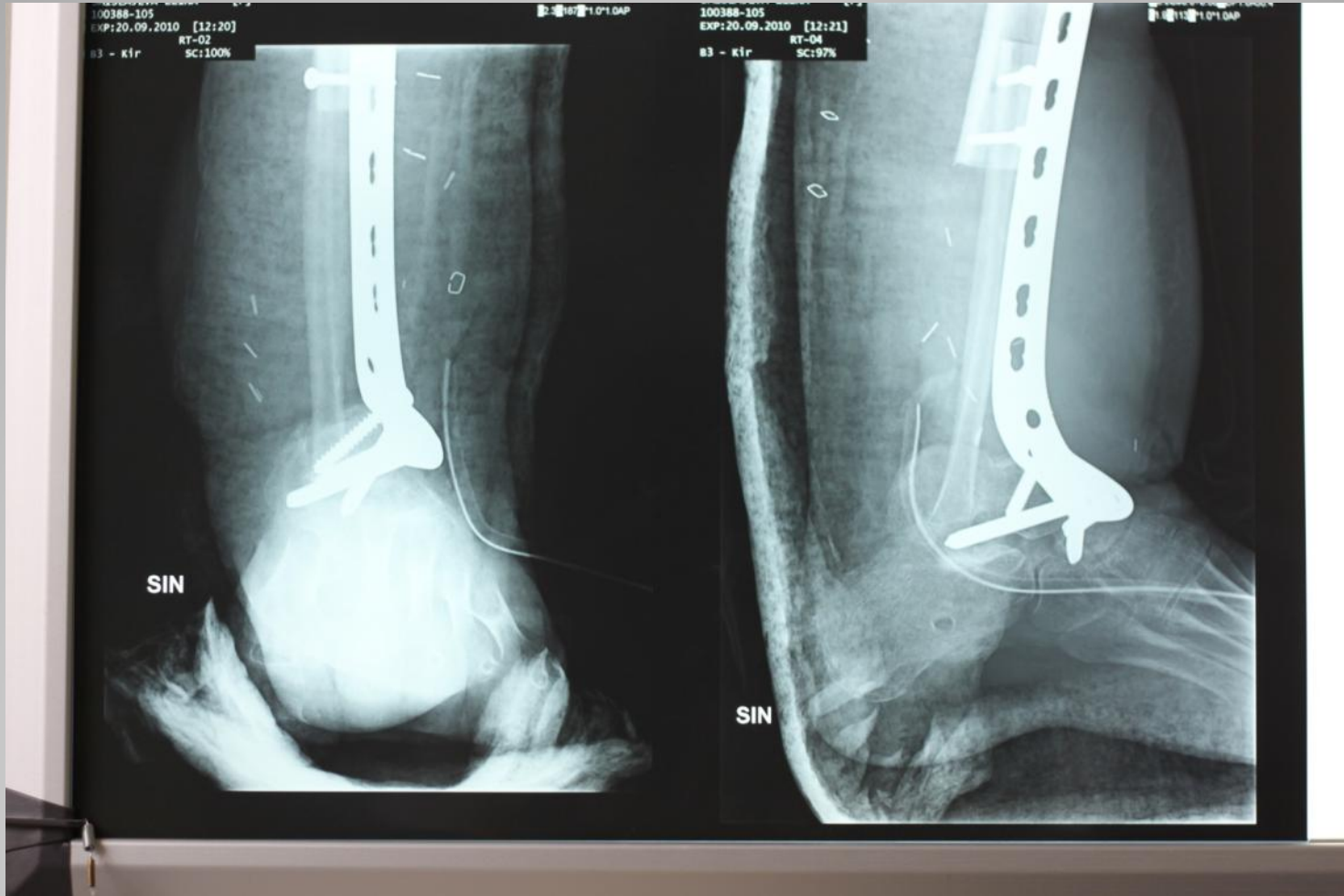


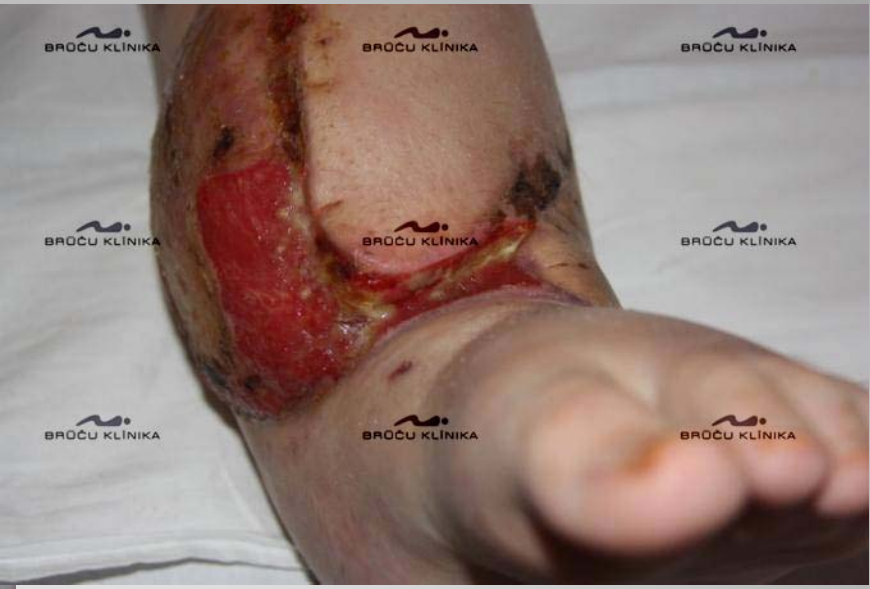
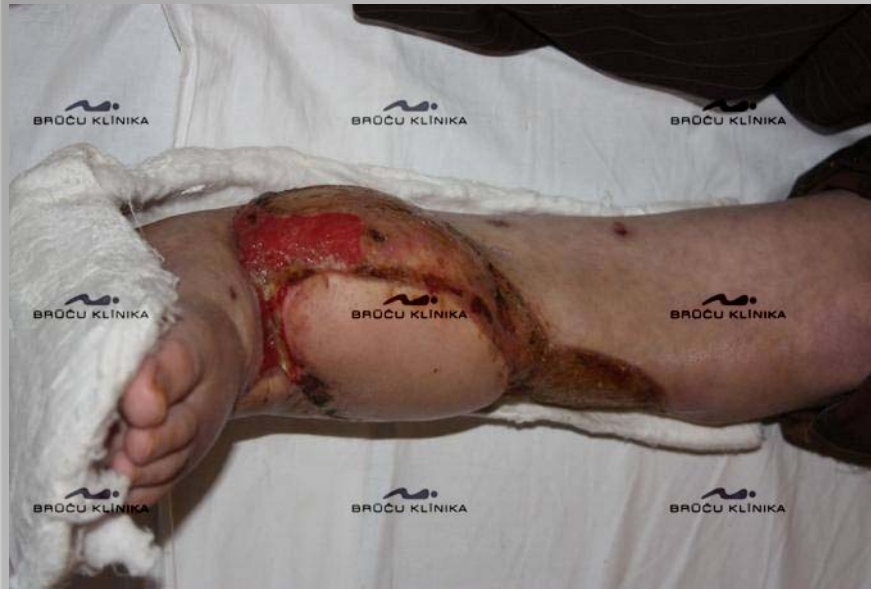


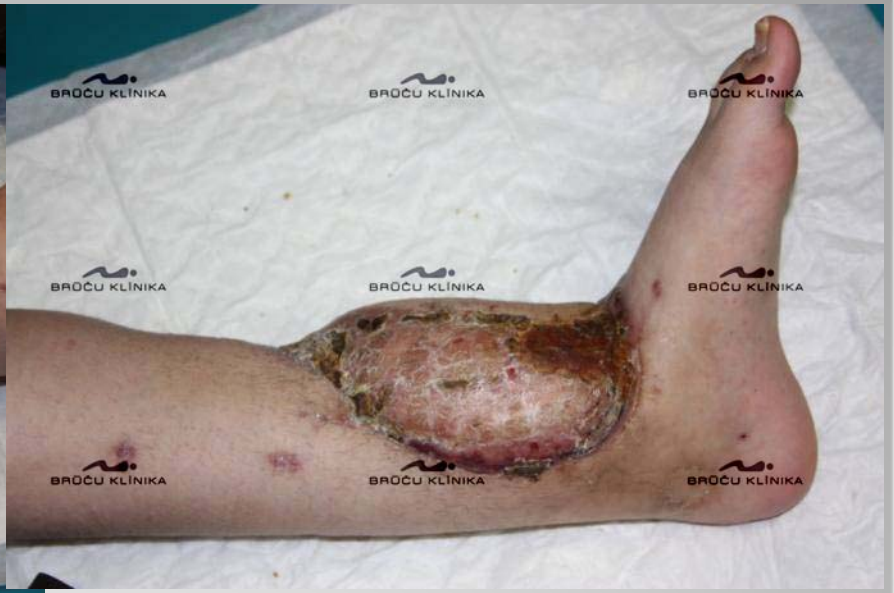
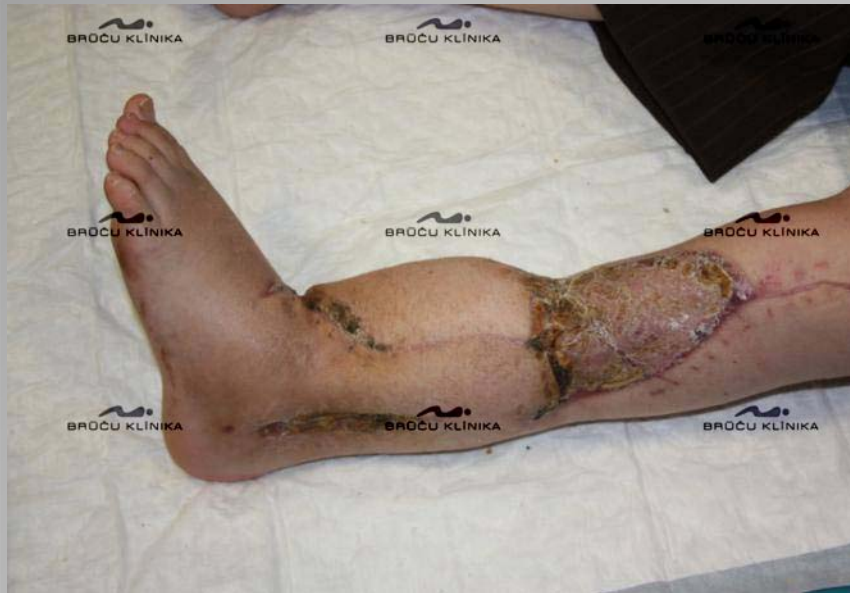



***Thank you for your attention!***